

## Delayed Death in Hanging

Venkatesh Maled

---

### Abstract

Hanging is a popular mean for suicide in India; the attempt frequently results in death. There are few cases reported in literature in which death has occurred after a certain period of time or the patient has survived after prolonged resuscitative measures. Most of such cases develop respiratory and neurological complications immediately after the incidence. Pulmonary edema is one of the most common complications that occur in patient of survivors of suicidal hanging. We report a case of suicidal hanging who developed pulmonary edema following the incidence.

**Keywords:** Hanging; Survival; Suicidal; Pulmonary Edema.

---

### Introduction

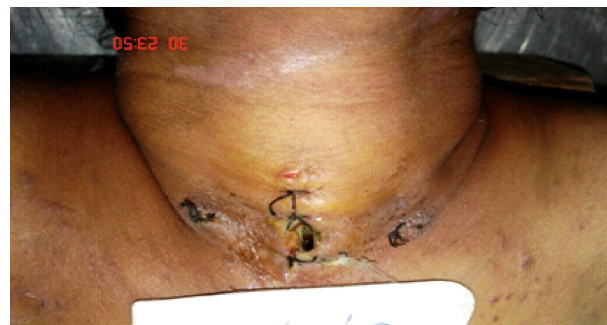
Hanging is a popular mean for suicide in India, the attempt frequently results in death[1]. In majority of cases death of the individual occur instantaneously. However, a few cases have been reported in literature in which death has occurred after a certain period of time or the patient has survived after prolonged resuscitative measures[2]. Most of the patients develop respiratory and neurological complications immediately after the incidence. Pulmonary edema is one of the most common complication that occur in patients immediately following their rescue from acute airway obstruction or suicidal hanging[3,4]. We report a case of suicidal hanging who developed pulmonary edema following the incidence. She presented in unconscious state with decerebrating movements to hospital. Intensive therapy was directed towards improvement in oxygenation, reduction in raised intracranial pressure and prevention of neurological consequences by cerebral resuscitation.

**Authors Affiliation:** Associate Professor, Dept of Forensic Medicine, SDM College of Medical Sciences & Hospital, Dharwad- 580009, Karnataka, India.

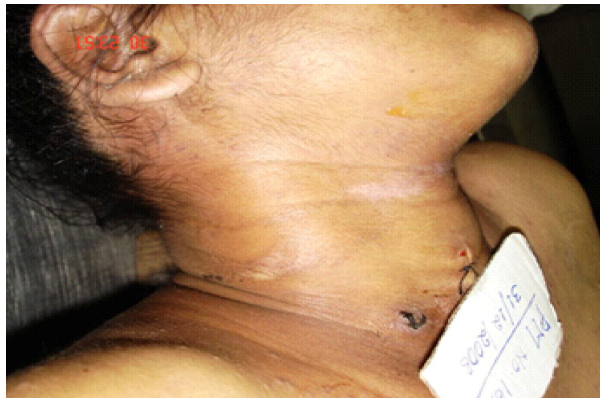**Reprints Requests: Venkatesh Maled,** Associate Professor, Dept of Forensic Medicine, SDM College of Medical Sciences & Hospital, Dharwad- 580009, Karnataka, India.  
E-mail: [drmaled\\_fm@yahoo.co.in](mailto:drmaled_fm@yahoo.co.in)

### Case Report

A 29 year old female was admitted to the hospital in an unconscious state. She was found hanging at her residence by her relatives, who brought her down from suspension immediately and she was rushed to the hospital in an unconscious state. She has clinically diagnosed to have suffered hypoxic ischemic encephalopathy and severe bronchospasm due to hanging. The patient was on mechanical ventilator for 17 days then she succumbed to pulmonary edema. Post mortem examination revealed partially healed ligature mark on the neck (Fig. 1, 2), with tracheostomy wound. No other external injuries present on the body. On further dissection of neck structures using bloodless dissection of neck technique, findings were unremarkable both in soft (neck muscles) and hard (hyoid bone) tissues.



**Fig. 1:** Partially healed ligature mark with tracheostomy wound



**Fig. 2:** Partially healed ligature mark with tracheostomy wound

## Discussion

Hanging is suspending the body by ligature material encircled around the neck, body weight acting as constricting force. Hanging is known as a painless mode of death with a very narrow failure rate[5]. It is a very common mode of suicide particularly in young adults[6]. Its incidence in India is approximately 25% of total cases of suicide[7].

In suicidal hanging cervical injuries are rare and death is often a slow process, which takes about 8-10 minutes. Death in suicidal hanging is secondary to hypoxia and cerebral ischemia due to compression of airway and major blood vessels of neck caused by ligature applied around the neck and the force of compression being the body weight[8]. If patient is rescued within few minutes of hanging, may be saved by applying specific resuscitative measures. However in judicial hanging death is instantaneous due to fall of body for few meters in the air, causing fracture and/dislocation of cervical vertebrae and vasovagal shock.

The clinical features of hanging involve respiratory and central nervous system. The common respiratory signs are respiratory distress, hypoxia, pulmonary edema etc. The signs related to CNS are like restlessness, unconsciousness, muscular rigidity, convulsions, amnesia, hemiplegia etc[8].

Deceased had unconsciousness, respiratory distress and hypoxia at the time of admission. She developed pulmonary edema during controlled ventilation through endotracheal tube followed by tracheostomy.

Pulmonary edema has been reported in literature following a sudden relief from upper airway obstruction[9]. Its onset is very rapid, generally appears within minutes of the event but some time it may be delayed. The cause of delay is not clear but it might be related to rate of onset of edema and severity

of airway obstruction.[4] The exact mechanism of development of pulmonary edema after rescue from hanging is still not clear. Some workers postulate that cerebral hypoxia during hanging causes release of vasoactive substances like histamine, serotonin and kinins. These mediators along with hypoxia lead to pulmonary vasoconstriction, pulmonary hypertension and pulmonary congestion.[10,11] Second theory suggests that pulmonary capillary membrane is damaged leading to increased capillary permeability and hence pulmonary edema [3]. Third theory suggests that the cause of pulmonary edema is hyperemia in the lungs. If pulmonary obstruction is suddenly removed there is an abrupt fall in intrapulmonary pressure, which suddenly increases the venous return and hence increases pulmonary hyperemia [11].

Thus any patient having hypoxia following rescue from hanging or relief from upper airway obstruction with clear chest may be considered as a case of hyperemia and such patient may develop delayed frank pulmonary edema during therapy.

Airway obstruction and compression of blood vessels in neck causes cerebral edema, hypoxic insult, raised intracranial pressure and neurological manifestation

To conclude, upper airway obstruction is a recognized mechanism that can produce non-cardiogenic pulmonary edema. Airway obstruction is the main cause of morbidity and subsequent mortality in the survivors of suicidal hanging. Pulmonary edema may develop subsequently in such patients. In most instances, post obstructive pulmonary edema is a reversible process once recognized and properly treated[12]. Hence irrespective of the condition after resuscitation in survivors of hanging patient even with clear chest must be treated with aggressive oxygen therapy and put on ventilator to prevent pulmonary edema.

## References

1. Pradeep KG, Kanthaswamy V. Survival in hanging. *Am J Forensic Med Pathol.* 1993; 14(1): 80-1.
2. Aggarwal NK, Kishore U, Agarwal B. Hanging-delayed death (a rare phenomenon). *Med Sci Law.* 2000; 40(3): 270-2.
3. Oswalt CE, Gates GA, Holmstrom. Pulmonary edema as a complication of acute air way obstruction. *JAMA.* 1977; 238: 1833-35.
4. Lang SA, Duncan PG, Shephard DA, Ha HC. Pulmonary oedema associated with airway obstruction. A Review. *Can J Anaesth.* 1990; 37: 210-18.

5. Gambhir Singh O, Sarma PC, Lepcha C. Near hanging: a case report. *J Punjab Acad Forensic Med Toxicol.* 2009; 9(1): 24-6.
6. Lowy A, Burton P, Briggs A. Increasing suicide rates in young adults. *Brit Med J.* 1990; 300: 643.
7. Trivedi JK, Srivastava R, Tandon R. Suicide: An Indian Perspective. *JIMA.* 2005; 103: 78-84.
8. Gorden I, Shapiro HA, Berson SD. Deaths usually initiated by hypoxic hypoxia or anoxic anoxia. *Forensic Medicine- A guide to principles.* 3<sup>rd</sup>ed 1998; 95-127.
9. Mantha S, Rao SM. Noncardiogenic pulmonary oedema after attempted suicide by hanging. *Anaesth.* 1990; 45: 993-4.
10. Fischman CM, Goldsmith MS, Gardner LB. Suicidal hanging an association with the adult respiratory distress syndrome. *Chest.* 1977; 71: 225-27.
11. Galvis AG, Stool SE, Bluestone CD. Pulmonary edema following relief of acute upper airway obstruction. *Ann Otol.* 1980; 89: 124-28.
12. Aggarwal R, Anant S, Harsh V. Pulmonary oedema in a survivor of suicidal hanging. *MJAFI.* 2004; 60: 188-9.

**Advertisement**





## Connecting Doctors

A revolutionary mobile application that can change the lives of the doctors. It is tailored made for doctors keeping in mind their every day needs and struggles. And its free.

 Stay Updated

 Get your Deeam Job

 Search and Connect

 Discuss & Reffer Cases

AVAILABLE ON